

## X-Rays and Thymus Gland

**Asadova Nigora Khamroyevna**

*Assistant of the Department of Anatomy, Clinical Anatomy (OSTA), Bukhara State Medical Institute,  
Bukhara, Uzbekistan*

**Abstract:** The study of the literature has shown that the morphological status of the thymus has been studied superficially in many works. The cellular composition of the thymus parts under the influence of physical or chemical environmental factors in the age aspect has not been studied enough. All this requires a more detailed study of the morphological changes occurring in this organ under the influence of various factors.

**The aim of the study** was to study the morphometric parameters of the cellular structures of the thymus of rats with a biostimulator ASD-2 fraction.

**Keywords:** thymus, T-lymphocyte, ASD-2 fraction, proliferation, apoptosis, immunity, Gassal's corpuscles.

**Introduction.** The thymus is the central organ of the immune system. At the early stages of ontogenesis, it controls and directs the structural and functional maturation of immunocompetent tissue, at later stages it ensures the safety and expediency of immunological reactions [3,6]. The thymus is a lympho-epithelial organ, its parenchyma is represented by a three-dimensional network of epithelial cells, the processes of which are interconnected by desmosomal contacts and form a kind of syncytium [3,5]. The gaps between epithelial cells are filled with lymphoid cells, mainly T-lymphocytes, which are at different stages of differentiation. They make up up to 90% of all thymus cells [2]. In addition, there are many cells of mesenchymal origin, primarily macrophages and interdigitating cells. The ratio of lymphocytes and non-lymphoid cells in the thymus cortex is approximately 100:1, in the medulla - 1:20 [3]. The medulla is also distinguished by the presence of thymic bodies (Gassal's bodies), which are formed by concentric layers of epithelial cells.

The histogenesis of the thymus is complex. It is the thymus that occupies a central place in the formation (in functional and morphological terms) of the immunogenesis system and the launch of the immune response in pathology [1,2]. In this regard, there is no doubt that the thymus is one of the most important central immune organs that regulate the body's protective resources in response to the ingestion of various kinds of antigens, and, in particular, genetically modified products [7]. At the same time, despite significant advances in the study of the structure and function of the human thymus and experimental animals, there is still no data in the literature on the regularities of its morphogenesis after the use of ASD-2. Such data are extremely necessary to understand the general patterns of integrated action of all parts of the immune system after the use of ASD [4,6]. The new data will provide a morphological basis for substantiating the tactics of immunocorrecting and immunomodulating therapeutic measures for various immunodeficiency conditions of the body. In addition, they will help to establish morphological criteria for the reserve capabilities of the immune system at the organ and system levels. Meanwhile, the question of the regularities of morphological changes and cytodynamics in the thymus under the action of a biostimulator is poorly covered in the literature. It was most often considered in various pathological conditions of the thymus [1,7]. Therefore, it is possible to judge the structural changes of the thymus only indirectly from the data on the morphogenesis of the thymus in pathology and the immune response to other antigens.

Thus, there is no data in the literature on the regularities of changes in the structure and cytoarchitectonics in various zones of the thymus in response to the action of genetically modified

organisms. Literature data on the morphogenesis of the thymus under the action of ASD f 2 are absent or insufficient. Considering that in recent years GMOs have been used everywhere, it is not difficult to understand what danger they can pose to humans.

**Materials and methods.** The study was conducted on 50 mongrel rats; newborns, 3 and 6 months of age. All animals were kept in the same conditions of the vivarium. Rats of both control and experimental groups received the same daily diet. All laboratory animals were divided into 3 groups: the experimental group-animals that included soy flour in the total diet (at a dose of 0.02-0.04 g per 1 rat weighing 230-250 g for 30 days (n=20); the control group - animals that received only a total diet, without soy flour (n=15). Group 3-intact animals (n=15).

After 30 days of soy flour feeding, groups of laboratory animals were killed in a humane way, then an autopsy was performed. During the killing and autopsy of laboratory animals, the rules of biological safety and ethical principles of working with laboratory animals were observed.

To study the morphological parameters of the thymus, a macroscopic method (anatomical dissection) was used. After cutting out the material, fixation was carried out in 10% buffered formalin, then rinsing in water and dehydration in alcohols and compaction with benzene. After that, sections 4-6 microns thick were poured into paraffin and prepared, which were stained with hematoxylin and eosin. The sections were examined morphometrically using an eyepiece micrometer DN-107T/ Model CM001 CYAN cope (Belgium).

### Results and discussions.

In one-month-old baby rats, the diameter of the right internal thoracic artery varied from 121.4 to 165.4 microns, on average  $146.7 \pm 0.42$ , the left internal thoracic artery was equal to 121.2 to 166.6 microns, on average  $150.9 \pm 0.70$ . The width of the right internal thoracic vein ranged from 186.4 to 223.6, on average  $200.9 \pm 0.71$  microns, and the left is 195.7 to 234.4, on average  $210.2 \pm 0.25$ . The thickness of the capsule of the thymus of 1-month-old rats at the gate was on average  $6.3 \pm 0.41$ , at the anterior end on average  $8.7 \pm 0.32$ , and at the posterior end on average  $7.3 \pm 0.21$  microns. The diameter of the trabecula in the proximal part averaged  $13.4 \pm 0.6$ , in the distal part it is on average  $10.8 \pm 0.21$  microns. The depth of the trabecula averaged  $14.0 \pm 0.61$ . The area of the thymus lobule of 1-month-old baby rats is on average 72.1%.

The wall thickness of the trabecular artery of 1-month-old rats in the proximal part averaged  $17.1 \pm 0.25$ , and the veins averaged  $15.6 \pm 0.31$  microns, the inner diameter of the artery averaged  $23.4 \pm 0.13$ , and the veins averaged  $22.8 \pm 0.19$  microns.

The wall thickness of the trabecular artery of 1-month-old rats in the distal part averaged  $15.1 \pm 0.18$ , and the veins averaged  $15.2 \pm 0.23$  microns, the inner diameter of the artery averaged  $20.9 \pm 0.21$ , and the veins averaged  $17.4 \pm 0.37$  microns.

The thickness of the wall of the arteriole of the cortical layer was on average  $14.1 \pm 0.24$ , and the venules on average  $13.4 \pm 0.18$ ; the inner diameter of the arteriole of the cortical layer was on average  $16.3 \pm 0.41$ , and the venule is on average  $22.9 \pm 0.15$  microns.

The thickness of the wall of the arteriole of the medulla was on average  $13.4 \pm 0.26$ , and the venules on average  $13.1 \pm 0.11$ ; the inner diameter of the arteriole of the medulla was on average  $15.6 \pm 0.3$ , and the venules is on average  $17.2 \pm 0.12$  microns.

In 3-month-old baby rats, the diameter of the right internal thoracic artery ranged from 167.4 to 190.1 microns, on average  $176.3 \pm 0.92$ , the left internal thoracic artery was 153.5 to 187.7 microns, on average  $172.8 \pm 0.28$ . The width of the right internal thoracic vein ranged from 226.1 to 263.2, on average  $247.9 \pm 0.64$  microns, and the left is equal to 202.8 to 251.4, on average  $220.2 \pm 0.15$ .

The thickness of the thymus capsule of 3-month-old baby rats at the gate was on average  $5.8 \pm 0.11$ , at the anterior end on average  $8.1 \pm 0.19$ , and at the posterior end on average  $6.9 \pm 0.31$  microns. The diameter of the trabecula in the proximal part averaged  $12.9 \pm 0.7$ , in the distal part it is on average

9.2±0.34 microns. The depth of the trabecula was on average - 13.2 ± 0.51. The area of the thymus lobule of 3-month-old baby rats is on average - 68.4%.

The wall thickness of the trabecular artery of 3-month-old rats in the proximal part averaged 18.4±0.22, and the veins averaged 16.3±0.21 microns, the inner diameter of the artery averaged 24.6±0.15, and the veins averaged 23.5±0.23 microns.

The wall thickness of the trabecular artery of 3-month-old rats in the distal part averaged 16.4±0.19, and the veins averaged 16.6±0.25 microns, the inner diameter of the artery averaged 21.6±0.31, and the veins averaged 18.7±0.22 microns.

The thickness of the wall of the arteriole of the cortical layer was on average – 15.7 ± 0.14, and the venules on average – 14.1 ± 0.13; the inner diameter of the arteriole of the cortical layer was on average – 17.4 ± 0.43, and the venule is on average – 23.4 ± 0.19 microns.

The thickness of the wall of the arteriole of the medulla was on average – 14.2 ± 0.16, and the venules on average – 14.3 ± 0.21; the inner diameter of the arteriole of the medulla was on average – 16.7 ± 0.27, and the venule is on average – 17.9 ± 0.13 microns.

The thickness of the wall of the arteriole of the medulla was on average – 15.6± 0.36, and the venules on average – 15.1± 0.11; the inner diameter of the arteriole of the medulla was on average – 17.8 ± 0.17, and the venule is on average – 18.1± 0.21 microns.

In 9-month-old rats, the diameter of the right internal thoracic artery varied from 221.5 to 252.8 microns, on average 242.3±0.34, the left internal thoracic artery was 218.2 to 259.4 microns, on average 230.8±0.25. The width of the right internal thoracic vein ranged from 206.7 to 323.2, on average 302.9±0.84 microns, and the left is equal to 272.5 to 311.3, on average 294.2 ± 0.42.

The thickness of the thymus capsule of 9-month-old baby rats at the gate was on average 3.9±0.41, at the anterior end on average 7.3±0.29, and at the posterior end on average 5.6± 0.11 microns. The diameter of the trabecula in the proximal part averaged 11.8 ± 0.17, in the distal part it is on average 8.1± 0.14 microns. The depth of the trabecula averaged 12.2±0.71. The area of the thymus lobule of 9-month-old baby rats is on average 53.7%.

The wall thickness of the trabecular artery of 9-month-old rats in the proximal part averaged - 20.3±0.18, and the veins averaged 18.8±0.34 microns, the inner diameter of the artery averaged 26.3±0.25, and the veins averaged 25.6±0.13 microns.

The wall thickness of the trabecular artery of 9-month-old rats in the distal part averaged 17.7±0.17, and the veins averaged 18.3±0.21 microns, the inner diameter of the artery averaged 23.7±0.31, and the veins averaged 19.8±0.4 microns.

The thickness of the wall of the arteriole of the cortical layer was on average – 17.3± 0.21, and the venules on average – 15.2± 0.13; the inner diameter of the arteriole of the cortical layer was on average – 19.1± 0.23, and the venules were on average – 25.2± 0.35 microns.

The thickness of the wall of the arteriole of the medulla was on average – 16.1 ± 0.19, and the venules on average – 16.6 ± 0.23; the inner diameter of the arteriole of the medulla was on average – 18.3± 0.33, and the venule is on average – 19.3± 0.15 microns.

In 12-month-old rats, the diameter of the right internal thoracic artery varied from 224.5 to 262.8 microns, on average 248.5±0.74, the left internal thoracic artery was 210.2 to 249.7 microns, on average 236.8±0.24. The width of the right internal thoracic vein varied from 297.1 to 330.4, on average 315.5±0.24 microns, and the left is 301.7 to 347.4, on average 311.2± 0.76.

The thickness of the thymus capsule of 12-month-old baby rats at the gate was on average 3.6±0.17, at the anterior end on average 6.3±0.09, and at the posterior end on average 5.0±0.31 microns. The diameter of the trabecula in the proximal part averaged 10.7±0.8, in the distal part it is on average 7.4± 0.34 microns. The depth of the trabecula averaged 11.5±0.71. The area of the thymus lobule of 12-month-old baby rats is on average 46.2%.

The wall thickness of the trabecular artery of 12-month-old rats in the proximal part averaged  $21.6 \pm 0.12$ , and the veins averaged  $19.3 \pm 0.14$  microns, the inner diameter of the artery averaged  $27.5 \pm 0.17$ , and the veins averaged  $26.7 \pm 0.23$  microns.

The wall thickness of the trabecular artery of 12-month-old rats in the distal part averaged  $18.5 \pm 0.17$ , and the veins averaged  $19.1 \pm 0.42$  microns, the inner diameter of the artery averaged  $24.5 \pm 0.23$ , and the veins averaged  $20.6 \pm 0.43$  microns.

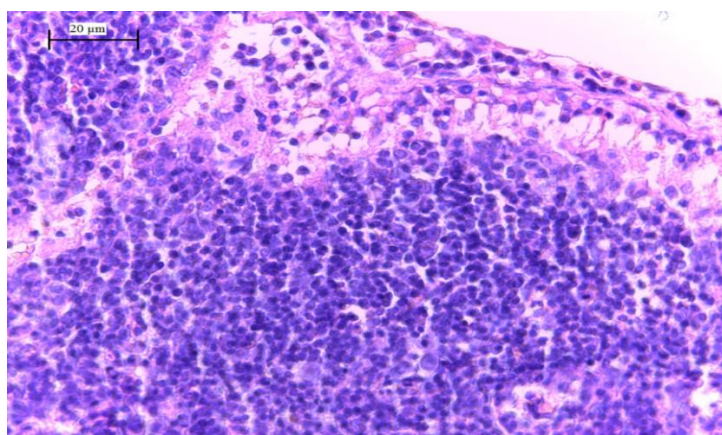
The thickness of the wall of the arteriole of the cortical layer was on average –  $18.2 \pm 0.19$ , and the venules on average –  $16.3 \pm 0.18$ ; the inner diameter of the arteriole of the cortical layer was on average –  $20.5 \pm 0.14$ , and the venules were on average –  $26.3 \pm 0.22$  microns.

The thickness of the wall of the arteriole of the medulla was on average –  $17.3 \pm 0.41$ , and the venules on average –  $17.2 \pm 0.24$ ; the inner diameter of the arteriole of the medulla was on average –  $19.1 \pm 0.19$ , and the venule is on average –  $20.2 \pm 0.23$  microns.

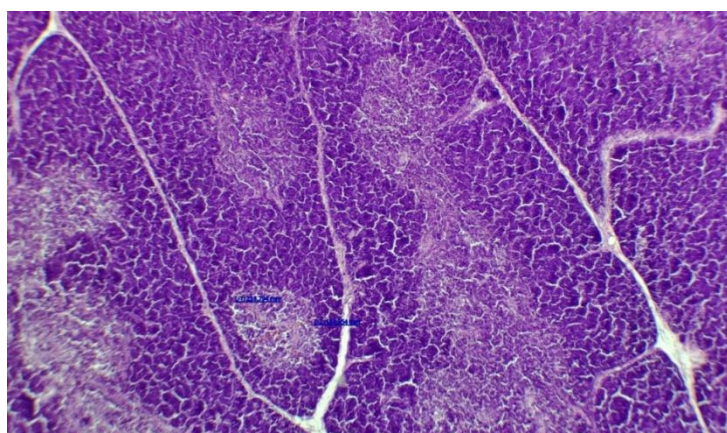
The results of the study show that in 3 months of rats, the thymus gland in 67.6% of cases consisted of 2 lobes and in 32.4% of one, multi-lobed forms were not detected.

Under the action of ASD, we did not detect any noticeable changes in anatomical parameters. The most pronounced changes are observed in the microscopic structure of the thymus gland.

In the experiment, the parenchyma of the thymus gland does not have a distinct division into cortical and medulla, and there is also an increase in small and large diameters of the medulla compared to the control.



**Fig. 1. A thymus lobule with a limited connective septum, numerous blood vessels in the septa are also visible. Staining with hemotoxylin and eosin.10x10.**



**Fig. 2. The thymus lobule is represented by two clearly distinguishable areas-cortical and medullary matter, connective tissue strands and vessels are also visible. Staining with hemotoxylin and eosin.10x10.**

**Table 1. The main morphometric features (area on slices, in %) of the structural components of rats are normal**

Structural components of the thymus	Area on slices (%)		
	X±Sx	min	max
1. cortical substance	56,1 ± 1,9	56,7	64,7
2. medulla	23,9 ± 1,9	18,2	28,3
3. cortical-cerebral index	1,3 ± 0,3	1,5	3,1
4. stroma	12,8 ± 0,6	8,6	11,6
(%) - the area of the structural component as a percentage of the area of the thymus			

Microscopic examination of the thymus after feeding ASD in animals revealed that a sharp reaction develops after certain periods after administration, i.e. underdevelopment, which progresses with an increase in the duration of the experiment. Thus, the results of morphological studies have shown that pathological changes often occur in rats when using ASD-2. Changes in the thymus when using ASD-2 should be taken into account when choosing treatment tactics and developing preventive measures for both immunodeficiency conditions and its complications.

**Conclusion.** The effect of ASD-2 on the thymus leads to a selective lesion between the parenchyma and stroma, perhaps these changes are based on a specific reaction of the thymus in response to the introduction of ASD, which leads to a weakening of immunity, the occurrence of allergic reactions, the formation of resistance to antibiotics and a decrease in the effectiveness of treatment and the process of accumulation in the body.

#### Literature:

1. Asadova N.Kh. Morphofunctional Changes in the Thymus Gland under the Influence of Psychogenic Factors // *Inernational Journal of Trend in Scientific Research and Development (IJTSRD)* // ISSN: 2456 – 6470 Special issue February 2021.P 78-81.
2. Khasanova D.A; Asadova N.Kh. Morphofunctional changes in thymus of white rats in acute stress//*ACADEMICIA: An International Multidisciplinary Research Journal* Vol. 11, Issue 1, January 2021.P 685-691.
3. Ш.Ж.ТЕШАЕВ, Н.Х.АСАДОВА МОРФОФУНКЦИОНАЛЬНЫЕ ОСОБЕННОСТИ ТИМУСА ПРИ ВОЗДЕЙСТВИИ РАЗЛИЧНЫХ ФАКТОРОВ ВНЕШНЕЙ СРЕДЫ//*Проблемы биологии и медицины* 2019, №4.2 (115) С 248-250
4. Асадова Н.Х Тешаев Ш.Ж. Морфофункциональные особенности тимуса в норме и при воздействии биостимулятора на фоне лучевой болезни // «Тиббиётда янги кун » 2/1 (30/1) 2020 С 194-196.
5. Алимова Н.П. Хасанова Д.А. Камалова Ш.М Асадова Н.Х.Ёш болаларнинг лимфарингиал халканинг патологияси билан комплекс даволашда замонавий фитопрепаратлари // *Тиббиётда янги кун* 4 (32) 2020 Б 484-485.
6. Asadova Nigora.Morphofunctional properties of the thymus and changes in the effect of biostimulants in radiation sickness // *Жамият ва инновациялар Special Issue – 3 (2021) / ISSN 2181-1415 Б 486-493.*
7. N.H.Asadova. Morphofunctional changes of the thymus under the influence of various environmental factors.//*The American Journal of Medical Sciences and Pharmaceutical Research. Volume 03 Issue 09-2021 | P: 102-109*