

Technique of Free Full-Thickness Autodermoplasty for Mammary Glands

Sardor U. Nazirov

Andijan State Medical Institute, Assistant Professor of the Department of Faculty and Hospital Surgery #1

Annotation: The study is based on the results of surgical treatment in 46 female patients with post-burn scar deformities of the soft tissues of the breast. According to the variations of scar deformity plastic surgery, all patients were divided into two groups. The main group included 24 patients in whom an improved method of full-thickness free skin grafting was applied, and the comparison group included 22 patients in whom the traditional method of free skin grafting with split-thickness autograft was used.

The proposed method of full-thickness autodermoplasty aims to improve graft survival by ensuring its tight adherence and reducing the risk of graft contraction.

The long-term results from the main group led to a reduction in the frequency of late complications from 33.3% to 8.3%, resulting in an improvement in the rate of favorable outcomes from 63.6% to 83.3%.

Keywords: mammary glands, burn, consequences of burns, reconstruction.

Relevance of the Issue: Post-burn deformities in the breast area represent destructive injuries, often leading to a deterioration in emotional well-being and quality of life for women [5,2]. Besides immediate stress relief, post-burn deformities often require prolonged treatment with numerous outpatient visits and multiple reconstructive surgical interventions, along with hospital stays [3,1]. These health-related consequences of burn injuries are often accompanied by an additional socio-economic burden on burn victims and their families [6].

The variety of methods for reconstructing post-burn scar deformities of the breast indicates the unresolved issue of the "ideal" material used in reconstructive surgery [4,7].

Aim of the study To improve the surgical treatment outcomes for patients with post-burn scar deformities of the breast.

Materials and Research Methods: The study is based on the results of surgical treatment of 46 female patients with post-burn scar deformities of the soft tissues of the breast. These patients were operated on in the reconstructive surgery department of a multi-profile medical center in Andijan region from 2020 to 2023.

Data were collected during initial and follow-up examinations, patient visits to the clinic for reassessment, and were analyzed using questionnaires. After the surgery, the degree of functional recovery and aesthetic outcomes were assessed. According to the variations in scar deformity plastic surgery, all patients were divided into two groups. The main group consisted of 24 patients who underwent an improved method of full-thickness free skin grafting, while the comparison group included 22 patients who received the traditional method of free skin grafting with a split-thickness autograft.

Free skin grafting with a split-thickness autodermograft.

Surgical Technique: This procedure is performed in a single stage. After incising the constricting scars down to healthy tissue, breast redraping is carried out. Hemostasis is meticulously ensured. The resulting wound is covered with a split-thickness skin graft harvested from the thigh region, with a

thickness of up to 0.6 mm, using a special instrument called a dermatome. The edges of the graft are sutured to the edges of the wound with non-traumatic nodal sutures. A furacin dressing is applied over the graft, and a moist-drying dressing is placed on the donor site.

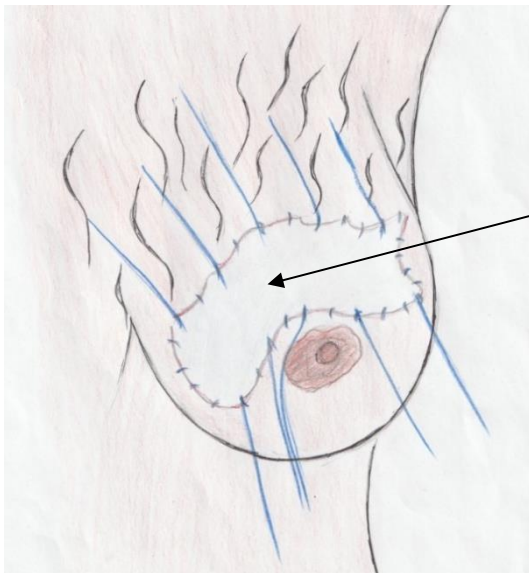
It should be noted that split-thickness autodermografts are prone to easy trauma, causing functional discomfort to patients. Retraction of the split-thickness skin graft necessitated reoperation.

When analyzing the consolidated results in the long-term period, 56.1% of good outcomes, 14.6% of satisfactory outcomes, and 29.3% of unsatisfactory outcomes were recorded.

The method of free full-thickness autodermoplasty.

The goal of the proposed method is to develop an approach to eliminate post-burn scar deformities that is technically simple, increases the likelihood of graft survival, leading to improved functional and aesthetic outcomes, reduces the duration of surgical treatment by optimizing graft survival and preventing scar contracture in the postoperative period.

The essence of the proposed method is as follows: constricting scars in the breast area are excised down to healthy tissues (subcutaneous fascia or muscles), and the breast is redraped into a symmetrical position on the opposite side. The wound is then closed with a free full-thickness autodermograft taken from the inner thigh. The edges of the graft and healthy tissues are sutured with non-traumatic nodal sutures. Long ends of threads, up to 10-12 cm, are left at regular intervals around the graft. Sterile gauze balls, ranging from 20 to 50 pieces, are then applied over the graft in the shape of a dome. The balls are applied in the following order: initially, they are applied around the periphery in 2 layers, and as they approach the center, the layer of balls increases to 7-8 layers, resulting in a semi-spherical shape. This is done to ensure even pressure on the transplanted graft. If the dressing is not shaped like a dome, it may become inverted when the knots are tied. Several sterile napkins (3-5) are then applied, and the remaining ends of the threads are tied opposite each other over the last napkins. This creates even pressure on the graft and the underlying healthy tissues without compromising tissue circulation around the graft. The donor site is sutured using a sharp dermatension technique. The dressing (Pelot) is removed after 15-20 days (Figure 1).



Free autodermotransplant

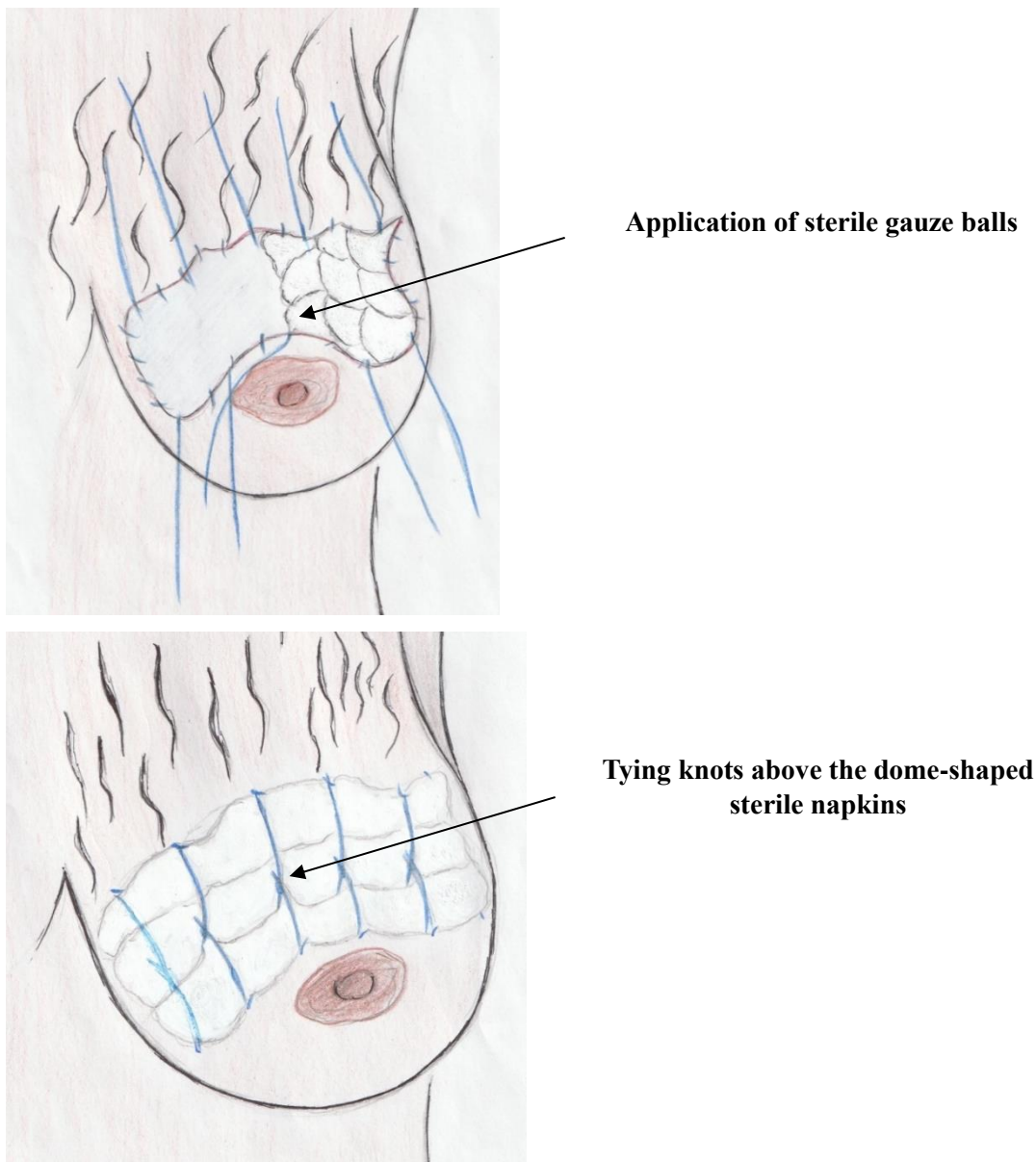


Figure 1. Diagram. Application of "Pelot" dressing

The advantages of the proposed technique include:

- Achieving optimal graft survival due to the close adherence of the autodermotransplant.
- Compared to the traditional technique (split-thickness autodermoplasty), the developed method is characterized by the absence of graft contraction in the long-term postoperative period.

When determining the frequency of long-term complications in the main group of 24 patients, long-term complications were noted in 2 cases (8.3%) – the formation of a pronounced hypertrophic scar and hyperpigmentation of the graft.

In the analysis of the consolidated results of plastic surgery, it is evident that the rate of good surgical treatment outcomes for post-burn scar defects of the breast increased from 63.6% to 83.3% ($\chi^2=6.126$; $Df=1$; $p=0.047$). In the main group, there were no unsatisfactory results, whereas in the comparison group, significant complications led to unsatisfactory results in 22.7% of cases.

Research Results: The long-term outcomes observed in 24 patients from the main group allowed for a reduction in the frequency of long-term complications from 33.3% to 8.3%, resulting in an improvement in the rate of good outcomes from 63.6% to 83.3% ($p=0.047$).

Conclusions: The method of free full-thickness autodermoplasty proposed by us is aimed at improving graft survival processes by ensuring its tight adherence and reducing the risk of graft contraction.

A patent for this proposed method has been granted by the Intellectual Property Agency of the Republic of Uzbekistan, Patent No. IAP 06815, dated March 28, 2022.

LIST OF REFERENCES

1. Alexeev A.A., Tyurnikov Y.I. Key statistical indicators of the work of burn centers in the Russian Federation for the year 2015 // Proceedings of the All-Russian Scientific and Practical Conference with International Participation "Thermal Injuries and Their Consequences." – Yalta, 2016. – P. 17-20.
2. Dmitriev G.I. Method of local skin grafting // Bulletin of the Russian Academy of Medical Sciences. 2013. No. 4. URL: <https://cyberleninka.ru/article/n/metod-mestnoy-kozhnoy-plastiki>.
3. Karimdjanov I.U., Rakhimov S.R., Madazimov M.M. Ways to improve the effectiveness of surgical treatment of post-burn scar deformities of the soft tissues of the trunk in children. Electronic scientific and practical journal. Combustiology. 2003. No. 14.
4. Kurbanov U.A., Saidov I.S., Davlatov A.A., Dzhanelilova S.M., Kholov Sh.I. Surgical treatment of post-burn scar deformities of the female breast // Avicenna Bulletin. 2018. No. 4. URL: <https://cyberleninka.ru/article/n/hirurgicheskoe-lechenie-posleozhogovyh-rubtsovyh-deformatsiy-zhenskoy-grudi>.
5. Madazimov M.M., Karimdjanov I.U., Sadykova M.A. Method of surgical treatment of post-burn scar deformities of the trunk // Surgery of Uzbekistan.- 2000.- No. 4.- P.27-29.
6. Kilburn N, Dheansa B. Socioeconomic impact of children's burns-a pilot study. Burns J Int Soc Burn Inj. 2014;40:1615-23. doi: 10.1016/j.burns.2014.03.006.
7. Wasiak J, Lee SJ, Paul E, Mahar P, Pfitzer B, Spinks A, et al. Predictors of health status and health-related quality of life 12 months after severe burn. Burns J Int Soc Burn Inj. 2014;40:568–74. doi: 10.1016/j.burns.2014.01.021.