

Ksharsutra Ligation in Fistula in Ano- a Single Case Study

Dr. Sai Chandrakant Kolte

M. S Ayurveda [Shalya Tantra-Samanya]

Dr. Manisha Pravin Pingle

M.S Ayurveda [Surgery]

Abstract: The anal fistula is a single tract or multiple tracts with an external opening in the modified skin or mucosa of anal canal or rectum. Prevalence of fistula in Ano is considered second to hemorrhoids among all anorectal abnormalities. Ksharsutra therapy in fistula in ano is appreciated much as compared to other Para surgical modalities. This disease causes discomfort and pain to patient, which creates problems in routine work. As the opening with wound located in perianal anal region, which is more prone for infection, thus takes long time to heal and the condition remains troublesome.

Keywords: Ayurveda, Fistula In Ano ,Ksharkarma Chikista, Case Study.

INTRODUCTION

Sushruta mentioned ksharkarma therapy), Agnikarma (heat therapy) and raktamokshan (blood therapy) are parasurgical procedures. Among them ksharkarma is the most accepted procedure to treat ano rectal disorders. Under ksharkarma forms are practiced among them “ ksharsutra (medicated thread) is useful to fulfil multi therapeutical uses with its pharmacological and surgicomedical action.

The word fistula is derived from Latin word “Reed” which means pipe or flute. It implies a chronic granulated track connecting two epithelial lined surfaces. These surfaces may be cutaneous or mucosal.

➤ Causes of fistula in ano-

- ✓ Crohn’s disease (an inflammatory disease of the intestine)
- ✓ Radiation (treatment for cancer)
- ✓ Trauma
- ✓ Sexually transmitted diseases
- ✓ Tuberculosis
- ✓ Diverticulitis (a disease in which small pouches form in the large intestine and become inflamed)
- ✓ Cancer

➤ The signs and symptoms of an anal fistula include-

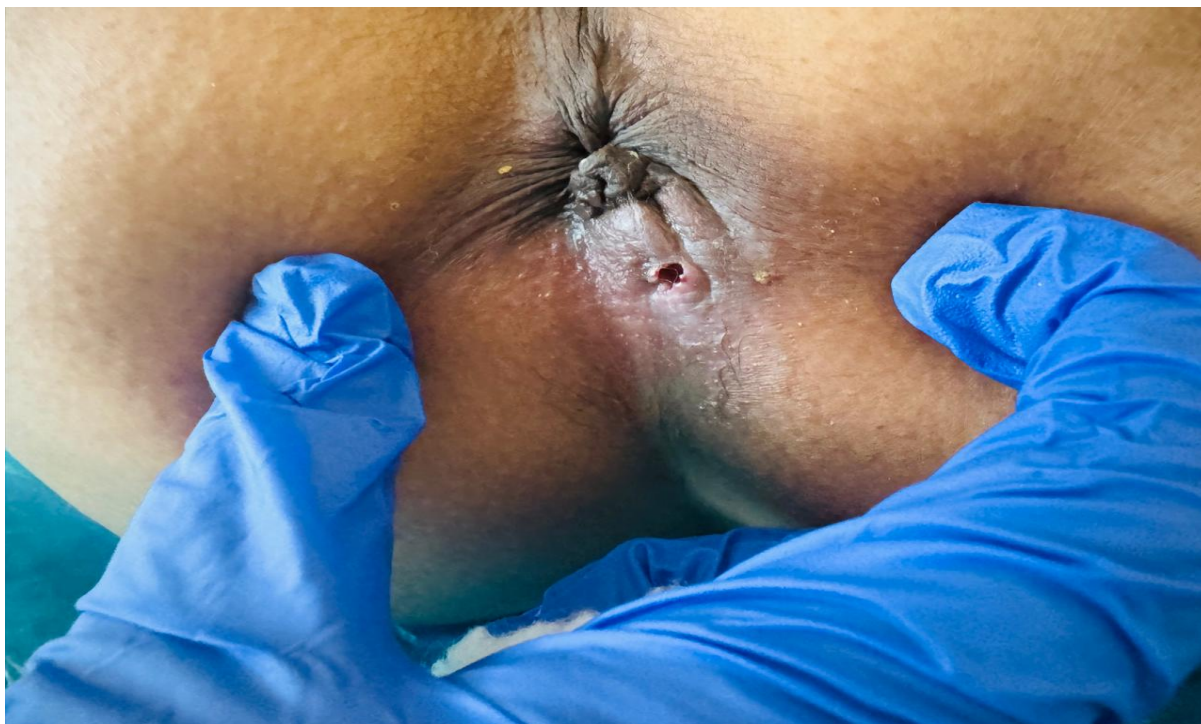
- ✓ Frequent anal abscesses
- ✓ Pain and swelling around the anus
- ✓ Bloody or foul-smelling drainage (pus) from an opening around the anus. The pain may decrease after the fistula drains.
- ✓ Irritation of the skin around the anus from drainage
- ✓ Pain with bowel movements
- ✓ Bleeding
- ✓ Fever, chills and a general feeling of fatigue

Fistula in ano is one of the most common ailments pertaining to ano rectal region. This disease causes discomfort and pain to patient, which creates problems in routine work. As the opening with wound located in perianal and anal region, which is more prone for infection, thus takes long time to heal and the condition remains troublesome. So that we used Ksharsutra therapy with great success and without recurrences. The standard ksharsutra (Apamarga ksharsutra) is prepared by repeated coatings of snuhi ksheera, Apamarga kshara churna and haridra churna.

Case Report:

A 45 yr old with 60kg male patient presented with sticky discharge from perianal region since 1 year in OPD of our clinic, Patient have past history of perianal abscess which is converted into fistula in ano. No any history of DM and hypertension. No any other medical or surgical history. Surgeon advised complete fistulectomy which may lead to recurrence of fistula with big sized perianal wound, which takes long time to heal and make uncomfortable to patient. So that patient consults to ayurvedic treatment. Local examination showed external at 3 o'clock position within 1cm from anal canal. Per rectal digital examination with lignocaine jelly 2% noted dimple felt at 3 o'clock, spasmodic sphincter tone. Proctoscopy examination also shows dimple at 3 o'clock with bulging at 3,7 and 11 o' degree internal hemorrhoids. Routine hematological, biochemical and microbiological investigations were carried out for medical fitness

Vitals of the patient were checked preoperatively and found that blood pressure 140/80 mm of Hg pulse 88/min and respiratory rate 24/min. Under spinal anesthesia this procedure of ksharasutra application was carried out after lord's manual anal dilatation.



Material and Methods:

The following equipment's and instruments are usually required during application

1. Lithotomy table.
2. Spot light.
3. Dressing trolley.

Instruments box which contains.

1. (curved probe with eyelet)3 Ara Shastra Mukhakriti (curved ed size.Vakra Eshani (curved probe with eyelet)3 assorted size
2. Vakra Eshani- Ara Shastra Mukhakriti probe with notch)
3. 3 assorted size. Eshani (malleable straight probe) 3"
4. Eshani (non –malleable straight probe) 3"
5. Sutra- Niyojini Shalaka (thread carrier) 2"
6. Darvikriti Shalaka (scooped Kshara applicator) 2"
7. Artery forceps (straight and curved) 3 pairs
8. Scissors (straight and curved) 1 pair.
9. Allis forceps 2 pairs
10. Proctoscope of various sizes 2 pairs
11. Apamarga Kshara sutra sealed thread.

PRE-PROCEDURE OF KHARSUTRA LIGATION:

After taking fitness from the physician evacuation of bowel with soap water enema was done and Inj. Tetanus toxoid 0.5ml intramuscular and Inj. Xylocaine 0.1ml intradermal as a test dose was given. Written informed consent was taken and under spinal anesthesia the patient was laid down on operation table in lithotomy position.

PROCEDURE OF KHARSUTRA LIGATION: -

After achieving spinal anesthesia, the patient is kept in proper lithotomy position and perineal region is cleaned with antiseptic lotion and draped. When the patient was reassured and gloved finger was gently introduced into rectum. Then a suitable selected probe was passed through the external opening of fistula. The tip of the probe was forwarded along the path of least resistance and was guided by finger in rectum to reach into the lumen of anal canal through the internal opening and tip was finally directed to come out of anal orifice. Then a

suitable length of plain thread sutra was taken and threaded into the eye of probe. Thereafter the probe was pulled out through the anal orifice to leave thread behind in the fistulous track. The two ends of the plain thread were then tied together with a moderate tightness outside the anal canal. This procedure is called primary threading and on second post operative day the apamarga ksharsutra application is done.

POST- PROCEDURE OF KHARSUTRA LIGATION :

Patient was instructed to take hot sitz bath before changing the tread. The apamarga ksharasutra was changed at weekly interval. The thread is tied to the previously applied apamarga ksharsutra in position toward outer end of the knot. Then an artery forceps is applied inner end to the same knot and the old thread is cut between the artery forceps along with the thread ultimately replaces the old thread by apamarga kshara sutra. Then two ends are ligated and bandaging is done. The same procedure is followed for successive changes of apamarga kshara sutra at weekly interval. At each sitting of changing of apamarga kshara sutra the length of previous kshara sutra is measured and recorded in the form of a graph on a proforma. This gives an idea of the amount of remaining tissue to be cut through each centimeter.

OBSERVATION AND RESULTS:

After 7th and 14th post operative days wound was with healthy granulated tissue. Between

21st to 31st Post operative days and also the sphincter relaxed. The ksharsutra was slough out in 6 successive setting of ksharsutra changing processing within 45 days after operative day and wound was healed completely. No any major complications were noticed during and

after the procedure. No recurrence was found after 6 month of follow up and the patient was satisfied by the procedure.

DISCUSSION:

Ksharsutra application is used in such a way that it can be carried out a day care procedure as it is a single setting procedure and the patient can go back home after 3rd day of procedure. Post operative complications and recurrence rate is negligible and patient can resume duties after removal of ksharsutra. Sitz bath with betadine solution and bowel regulators were advised and diet explained.

Hence ksharasutra ligation are more beneficial than modern surgery because in this method minimal post operative pain as ligation done after release of sphincter, post operative bleeding is minimal as wound is secured from all side, minimal medicines are required and local treatment is sufficient, also it is a cost-effective procedure and no any untoward effects were noted and hence quality of life improved.

CONCLUSION:

In fistula in ano application of ksharasutra is safe and easy to perform. So that it is a good alternative to surgery as it carries minimum complications and recurrence are almost negligible. Hence it is a good cost-effective procedure to manage fistula in ano.

REFERENCES:

1. Acharya JT. Susruta Samhita with Nibandhasangraha commentary of Dalhana. Reprinted. Varanasi (India): Chaukamba Sanskrit sansthan; 2009. p47.
2. Srikantha murthy KR. Bhavaprakasha. Reprinted. Varanasi academy; 2004.p312.
3. Bailey and Love. Fistula in ano. Short practice of surgery, 7th edition 2006.
4. Yadavji Trikamji. Dalhan commentary on sushruta samhita chikisasthan, chapter 36, verse37, chaukhmba Sanskrit pratisthan, 201.
5. Charaka samhita, edited by vidya Yadavji Trikamji Acharya. siddhisthan chapter 6,verse no.62. chaukhamba prakashana, Varanasi, 2008.
6. ameya tagalpallewar ,dr.vihar bidwai dr.https://ijrar.org/track.php?r_id=240345