

Pathologic Mammography Findings in Symptomatic and Asymptomatic Patients in a Nigerian Population

Daniel Chimuanya Ugwuanyi¹, Egwuonwu Victor Afamefuna^{2*}

¹Department of Radiography and Radiological Sciences, Faculty of Health Sciences and Technology, Nnamdi Azikiwe University, Nnewi Campus, Anambra State, Nigeria

^{2*}Department of Medical Rehabilitation (Physiotherapy), Faculty of Health Sciences, Nnamdi Azikiwe University, Nnewi Campus, Nigeria

Email: ¹dc.ugwuanyi@unizik.edu.ng, ^{2*}va.ugwuanyi@unizik.edu.ng (Corresponding author)

Abstract:

Breast cancer is a serious and harmful disease. It has therefore become pertinent to undergo annual mammography screenings or check-ups when abnormal changes are suspected, ensuring that both women and men are adequately protected from the detrimental effects of breast cancer before it metastasizes. The purpose of this study was to compare the pathologic mammography findings in symptomatic and asymptomatic patients in a Nigerian population. A total of 154 mammography data were collected by the researcher, analyzed, and inferences were made based on the results. The research design adopted was a retrospective study. The sample size of 154 was obtained from patients' request cards and radiologic reports stored in the diagnostic centres' information systems. Among the data collected, 3 were male and 151 were female. The most frequent clinical indication presented was mastodynia (breast pain), with a frequency of 61. The most common age group was 44–53 years. Radiologic findings were predominantly normal in 121 cases (78.6%). Based on BIRADS classification, the most common category was BIRADS I (normal), occurring in 84 cases (54.5%). Among asymptomatic patients, the predominant finding was normal, while in symptomatic patients, calcifications were most commonly observed.

Keywords: Breast Screening, Mammography, Breast Health, Diagnostic Imaging, Early Detection, Radiodiagnostic Centres, Imo State.

Introduction

Mammography (also called mastography) is the radiographic examination of the breast tissue (soft tissue radiography) using low energy x-ray (usually around 25-35KVp) [1]. It is a specialized form of X-ray imaging of the breast used to screen women at risk for breast cancer and to aid in the diagnosis of breast cancer in symptomatic patients [2]. It could be used as a diagnostic or screening tool [3]. The goal of mammography is the early detection of breast cancer, typically through the detection of characteristics masses and/or micro calcifications. Like all x-rays, mammogram uses doses of ionizing radiation to create images. These images are analyzed for any abnormal findings. It is normal to use lower energy X-rays, typically Mo (k-shell X-ray energies of 17.5 KeV and 19.6KeV) and Rh (20.2 KeV and 22.7 KeV) than those used for the radiography of the bones (Reilly, 2015). For the average women between the ages of 50 and 74, the American college of Radiology and American Cancer Society recommended yearly screening mammography starting at the age 40. The Canadian Task Force on preventive healthcare (2012) and European Cancer observatory (2011) recommends mammography every 2-3 years for women between 50 and 69 years [4]. Additionally, mammography should not be done on any increased frequency in people undergoing breast surgery, including breast augmentation, breast reduction and mastopexy.

The breasts are glandular organs that sit atop the chest wall and pectoral muscles. The breasts are present in both sexes. However, the female breasts are more developed. The breasts are also an important component of the female reproductive system [5]. Screening mammography and Diagnostic

mammography are the two types of Mammography breast examination. The use of mammography, as a screening tool, is to detect breast change in asymptomatic women who are without any sign or symptom, or observable breast anomalies. They are performed yearly on patients who present no symptom. The goal is to detect cancer before any clinical sign are noticeable. Keen and Keen 2019, indicated that repeated mammography starting at age 50 saves about 1.8 (overall range, 0.9–2.7) lives over 15 years for every 1000 women screened. The result has to be seen against the negatives of errors in diagnosis, over treatment and radiation exposure. In screening mammography, both head-to-foot (craniocaudal, CC) view and angled side-view (Mediolateral oblique MLO) images of the breast are taken.

Diagnostic mammography is used to investigate suspicious breast changes such as breast lump, breast pain, unusual skin appearance, nipple thickening or nipple discharge [6]; also, it is used to evaluate abnormal findings on a screening mammogram. It is done on symptomatic patients. It may include geometrically magnified and spot compressed views of the particular area of concern. It is usually time consuming and costlier than screening mammography. The goal of diagnostic mammography is to pinpoint the exact size and location of a breast abnormality. If the finding seen with diagnostic mammography is suspicious, additional breast imaging (such as ultrasound) or a biopsy may be ordered [7].

Mammographic findings are based on the assessment of the breast density. Breast density describes the proportion of tissue density that makes up a female breast. It comprises the area of radiodense glandular tissue to the radiolucent areas of fat [8]. It tells how much fibro glandular (glandular and connective) tissue versus fatty tissue that is present in the breast. Breast tissue ranges from Fibro glandular which appears white; to fatty tissue which appears gray or dark as seen on a mammogram. Breasts are made up of glandular tissues and the stroma tissues [9]. The glandular part of the breast includes the lobules and ducts. Anatomically, each breast has several ducts that lead out to the nipple. The stroma i.e. the supporting tissues of the breast include the fibrous connective tissue and fatty tissues that give the breast its size and shape [10]. Mammographic breast density is a measure of parenchymal breast pattern on radiographs. It also has a hormonal influence. The breast epithelium and stroma attenuate x-ray more than fat and thus appears light on mammograms while fat appears dark [11].

High breast tissue density means there is greater amount of glandular tissue compared to fats. It is usually common among young people and it's of importance because increased breast tissue density is associated with lower sensitivity of mammography, this actually obscures neoplasm of the breast [12]. Ultrasonography could be used as an alternative image modality to access the client of this group. Increased mammography breast density is a risk factor for breast cancer [12]. Low breast tissue density means there is greater amount of fat compared to glandular and connective tissues [13].

Breast density is influenced by some factors which include hormone replacement therapy, estrogen level, pregnancy, lactation, weight loss, breast cancer and inflammation of the breast. It is strongly inversely associated with parity. On the other hand, factors that decreased breast density include the medication, Vitamin D and Calcium intake in premenopausal women, acromegaly, increasing weight and age [14]. Risk factors for breast cancer include age, genetic mutation, early menstrual period, late or no pregnancy, menopause after age 55, obesity, use of combination hormone therapy, taking oral contraceptives, family history of breast cancer, previous treatment using radiation therapy, alcohol consumption [15], [16].

The study was aimed to provide a comprehensive evaluation among women referred for both diagnostic and screening mammography, their frequencies, awareness and possible most occurring outcome of the investigation.

Methodology

This research adopted a retrospective study design, focusing on mammography examinations conducted between January 2023 and June 2024 across selected private radiodiagnostic centers in Imo State, Nigeria, including Everight Diagnostic and Laboratory Services Limited, Owerri. Data were sourced from patients' request cards and radiologists' reports stored in the diagnostic centers' information systems, capturing all cases of mammography performed within the specified period.

The study population comprised all patients who underwent mammography during the aforementioned time frame. A sample size of 154 was calculated from a total population of 250 using the Yaro Yamane formula (equation 1) with a 5% margin of error and a 95% confidence level. A cluster sampling technique was employed to select participants. Ethical approval was obtained from Nnamdi Azikiwe University Teaching Hospital, Nnewi, and from the management of the participating diagnostic centers. The inclusion criteria involved patients whose mammography records were complete and included both provisional and final diagnoses, while records with incomplete data or undetermined patient age were excluded. Key parameters collected for analysis included patients' age, sex, clinical indications, mammographic findings, and final diagnosis.

The collected data were analysed using Statistical Package for Social Sciences (SPSS) version 21.0, applying both descriptive and inferential statistics, with a statistical significance level set at $p < 0.05$.

The Yaro Yamane formula as stated by Uzuagulu, 2011 is given by;

$$n = \frac{N}{Ne^2 + 1} \quad (1)$$

where; n = Sample size; N = Population size; e = 5% acceptance error limit (level of significance); Confidence level = 95%; 1 = Constant

Then, with N=250 and e= 0.05

$$\text{Sample size (n)} = \frac{250}{250(0.05)^2 + 1}; \text{ therefore n=154}$$

Method of Data Analysis

Data were analyzed using Statistical Package for Social Sciences (SPSS) Version 21.0. Statistical significance will be set at $P < 0.05$. Both descriptive and inferential statistics will be generated and presented on tables and charts.

Result

Table 1. The gender distribution of the patients

Gender	Frequency	Percentage
Male	3	2.0
Female	151	98.0
TOTAL	154	100.0

The total number of data used was 154, the females were higher with frequency of 151(98%) while male have frequency of 3(2%) as shown in table 1.

Table 2. The age distribution of the patients.

Age	Frequency	Percent
23-33	11	7.1
34-43	20	13.0
44-53	64	41.6
54-63	37	24.0
64-73	12	7.8
74-83	10	6.5
TOTAL	154	100.0

It was deduced that the highest occurring age group of the patients is 44-53 years with frequency of 64(41.6%), while the least age range is 23-33 years with a frequency of 11(7.1%) as shown in Table 2.

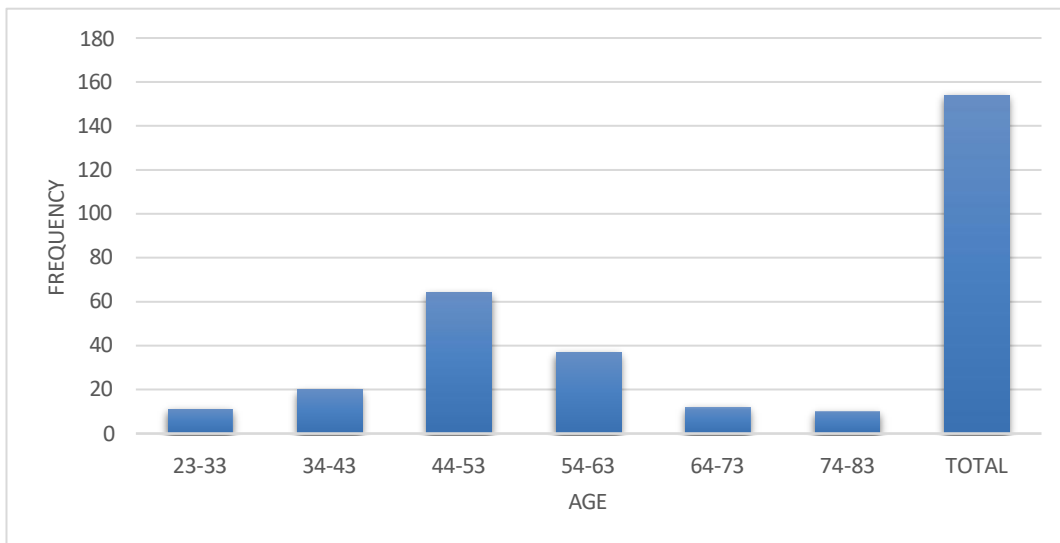


Figure 1. A bar chart showing the frequency and percentage distribution of patients' clinical mammography history.

Table 3. Clinical History.

Clinical history of patients	Frequency	Percent
Breast mass	12	7.8
Nipple discharge	8	5.2
Cancer	9	5.8
Fibroadenoma	21	13.6
Mastitis	15	9.7
Mastodynia	61	39.6
Breast swelling	10	6.5
Breast heaviness	18	11.7
Total	154	100.0

From the table 3, the most common presenting clinical history is mastodynia (breast pain) with frequency of 61(39.6%), the least occurring clinical history is nipple discharge with a frequency of 8(5.2%).

Table 4. Radiological Findings.

	Frequency	Percentage
Normal	121	78.6
Benign	24	15.6
Malignant	9	5.8
Total	154	100.0

The frequency of patients that have normal findings is 121(78.6%), the frequency of benign findings is 24(15.6%), and while that of malignancy is 9(5.8%) as shown in table 4.

Table 5. Classification according to BIRAD system.

Classification	Frequency	Percent
Negative (BIRAD 1)	84	54.5
Benign findings (BIRAD 2)	24	15.6
Probably benign (BIRAD 3)	19	12.3
Suspicious abnormality (BIRAD 4)	12	7.8
Highly suspicious malignant (BIRAD 5)	9	5.8
Proven biopsy malignant (BIRAD 6)	6	3.9

Total	154	100.0
--------------	------------	--------------

According to BIRAD system of classification, Negative (BIRAD 1) finding happen to occur most with a frequency 84(54.5%), and the least occurring proven biopsy malignant (BIRAD 6) has the frequency of 6(3.9%) as shown in table 5.

Table 6. Distribution of Asymptomatic Patients and Corresponding Radiological Findings.

Findings	Frequency	Percentage
Asymmetric density	16	10.4
Isodense lesion	19	12.3
Benign calcification	28	18.1
Normal	67	43.5
Benign nodular mass	8	5.3
Axillary lymphadenopathy	9	5.8
Cutaneous skin thickening	7	4.5
Total	154	100.0

In table 6, from the distribution of asymptomatic patients, the most occurring is normal with the frequency of 67(43.5%), while the least occurring is cutaneous skin thickening with a frequency of 7(4.5%).

Table 7. Most Common Benign and Malignant Radiological Findings.

Findings	Frequency	Percentage
Asymmetric	10	6.5
Isodense lesion	11	7.1
Calcifications	54	35.1
Cyst lesion	10	6.5
Axillary lymphadenopathy	48	31.2
Breast nodular mass	7	4.5
Gynaecomastia	4	2.6
Extensive micro calcifications	3	1.9
Nipple retraction	7	4.5
Total	154	100.0

Table 7 shows the common benign and malignant radiological findings with calcification being the most common benign findings with a frequency of 54(35.1%), and Gynecomastia as the least with frequency of 4(2.6%), for malignancy, they are extensive micro-calcifications with frequency of 3(1.9%), and nipple retraction with frequency of 7(4.5%).

Discussion

The result of this study showed that out of a total of 154 patients examined, the majority were females, making up 98.0% (n = 151), while only 2.0% (n = 3) were males. This reflects the global trend that breast-related health issues requiring mammographic evaluation are predominantly found in females; this is also in line with the statements by Hill et al. [17]. The age distribution revealed that most of the patients were between the ages of 44 to 53 years, accounting for 41.6%, followed by those aged 54 to 63 years with 24.0%, and 34 to 43 years with 13.0%. This suggests that middle-aged to older adults are the most common age group presenting for mammography.

In terms of clinical presentation, the most frequently reported symptom was mastodynia (breast pain), which made up 39.6% of the cases, this agrees with the findings of [18], [19] in their respective works. This was followed by fibroadenoma (13.6%), breast heaviness (11.7%), mastitis (9.7%), and breast mass (7.8%). Other clinical indications included breast swelling, nipple discharge, and suspected cancer. These findings indicate that while some patients came with clearly suspicious symptoms like masses and cancer, others presented with non-specific symptoms such as heaviness and pain, which may or may not indicate a pathological finding.

From the radiological findings, a large percentage (78.6%) of the patients had normal mammographic results, while 15.6% had benign findings, and only 5.8% had malignant features. This shows that although a good number of patients presented with symptoms, most did not have serious pathological outcomes. When classified using the BIRAD (Breast Imaging Reporting and Data System), 54.5% of patients were categorized as BIRAD 1 (negative), while 15.6% were BIRAD 2 (benign), and 12.3% were BIRAD 3 (probably benign). A smaller proportion fell into the suspicious and malignant categories: 7.8% were BIRAD 4, 5.8% were BIRAD 5 (highly suspicious of malignancy), and 3.9% were BIRAD 6 (biopsy-confirmed malignancy). This further confirms that majority of the patients had non-malignant outcomes, showing that most of the findings are ‘Negative’ (BIRAD 1), the changes could be as a result of maternal intravenous fluid and postpartum breast changes [20].

Among the asymptomatic patients, 43.5% had normal mammographic findings, while the rest had abnormalities like benign calcifications (18.1%), isodense lesions (12.3%), and asymmetric densities (10.4%). Other notable findings in this group include axillary lymphadenopathy, cutaneous skin thickening, and benign nodular masses, showing that even in the absence of symptoms, mammography could still detect early or hidden breast abnormalities.

Finally, in the overall analysis of common benign and malignant radiological findings, calcifications were the most prevalent, accounting for 35.1%, followed by axillary lymphadenopathy (31.2%), isodense lesions (7.1%), and asymmetric densities and cystic lesions (both 6.5%). Nipple retraction and breast nodular masses were also reported, though at lower rates. These findings highlight the importance of mammography not only in detecting malignancy but also in identifying a wide range of benign and early warning signs of breast pathology in both symptomatic and asymptomatic individuals.

Conclusion

This study employed a retrospective design, focusing on the analysis of mammography examinations. Mammography remains the primary imaging modality for evaluating breast pathology and has been clinically validated to significantly reduce breast cancer mortality through early detection [21]. The production of high-quality mammographic images plays a crucial role in the effective screening and management of breast cancer.

The research was conducted in a single diagnostic center and included a total of 154 participants, comprising both symptomatic patients with clinical histories and asymptomatic individuals. Among the asymptomatic group, the most frequently observed finding was normal breast tissue, whereas calcifications were the predominant radiologic finding among symptomatic patients.

Given the outcomes of this study, it is recommended that individuals undergo routine annual screening mammography to facilitate early detection of breast cancer, thereby contributing to a reduction in mortality rates. Additionally, the integration of other imaging modalities alongside mammography is advised to promote diagnostic accuracy and ensure comprehensive breast evaluation.

References

- [1] A. L. Jannetta, *Advanced Deconvolution Techniques and Medical Radiography*. Newcastle, U.K.: Univ. of Northumbria, 2005.
- [2] R. M. Reilly, Ed., *Medical Imaging for Health Professionals: Technologies and Clinical Applications*. Hoboken, NJ, USA: John Wiley & Sons, 2019.
- [3] K. C. Oeffinger *et al.*, “Breast cancer screening for women at average risk: 2015 guideline update from the American Cancer Society,” *JAMA*, vol. 314, no. 15, pp. 1599–1614, 2015.
- [4] G. I. Balali, “Breast cancer: A review of mammography and clinical breast examination for early detection,” *Open Access Library Journal*, vol. 7, no. 10, p. 1, 2020.
- [5] G. Bistoni *et al.*, “Anatomy and physiology of the breast,” *Surgery (Oxford)*, vol. 42, no. 12, pp. 859–864, 2024.
- [6] B. Jasra, S. Sharma, and A. Deladisma, “Evaluating patients with breast concerns: Lump, pain, and mastitis,” *SAT*, vol. 19, p. 23, 2023.
- [7] E. I. Obeagu and G. U. Obeagu, “Breast cancer: A review of risk factors and diagnosis,”

Medicine, vol. 103, no. 3, p. e36905, 2024.

- [8] C. Comparetto and F. Borruto, “Cutting-edge imaging breakthroughs for early breast cancer detection,” *Cancer Screening and Prevention*, vol. 4, no. 1, pp. 21–39, 2025.
- [9] N. S. Winkler, S. Raza, M. Mackesy, and R. L. Birdwell, “Breast density: Clinical implications and assessment methods,” *Radiographics*, vol. 35, no. 2, pp. 316–324, 2015.
- [10] F. Kakulas and D. Geddes, “Anatomy of the human mammary gland: Current status of knowledge,” *Journal of Clinical Anatomy*, vol. 26, no. 1, pp. 29–48, 2013.
- [11] N. F. Boyd *et al.*, “Breast tissue composition and susceptibility to breast cancer,” *JNCI: Journal of the National Cancer Institute*, vol. 102, no. 16, 2010.
- [12] S. S. Nazari and P. Mukherjee, “An overview of mammographic density and its association with breast cancer,” *Breast Cancer*, vol. 25, no. 3, pp. 259–267, 2018.
- [13] K. Ghosh *et al.*, “Tissue composition of mammographically dense and non-dense breast tissue,” *Breast Cancer Research and Treatment*, vol. 131, no. 1, pp. 267–275, 2012.
- [14] L. Straub *et al.*, “Mammographic density and vitamin D levels—A cross-sectional study,” *Geburtshilfe und Frauenheilkunde*, vol. 77, no. 3, pp. 257–267, 2017.
- [15] [15] G. Curigliano and C. Criscitiello, “Successes and limitations of targeted cancer therapy in breast cancer,” 2014.
- [16] [16] N. Kumar *et al.*, “The unique risk factor profile of triple-negative breast cancer: A comprehensive meta-analysis,” *JNCI: Journal of the National Cancer Institute*, vol. 116, no. 8, pp. 1210–1219, 2024.
- [17] T. D. Hill, H. J. Khamis, J. E. Tyczynski, and H. J. Berkel, “Comparison of male and female breast cancer incidence trends, tumor characteristics, and survival,” *Annals of Epidemiology*, vol. 15, no. 10, pp. 773–780, 2005.
- [18] E. R. U. Ebubedike *et al.*, “Pattern of mammographic findings among symptomatic females referred for mammography in South East Nigeria,” *West African Journal of Radiology*, vol. 23, pp. 23–27, 2016.
- [19] O. A. Egwuonwu *et al.*, “Breast pain: Clinical pattern and aetiology in a breast clinic in Eastern Nigeria,” *Nigerian Journal of Surgery*, 2016.
- [20] G. Vivod, S. Merlo, and N. Kovacevic, “High-grade serous ovarian cancer during pregnancy: From diagnosis to treatment,” *Current Oncology*, vol. 31, no. 4, pp. 1920–1935, 2024.
- [21] M. G. Cerdas *et al.*, “Exploring the evolution of breast cancer imaging: A review of conventional and emerging modalities,” *Cureus*, vol. 17, no. 4, 2025.