

Morphofunctional Differentiations of the Spleen of White Rats in Normal and Abnormal Conditions

M. R. Turdiev

Bukhara state medical Institute

Annotation: In an experimental study, morphofunctional features of the spleen of 3-month-old white rats in normal and chronic radiation sickness were studied. In the lymph nodes of the spleen of irradiated rats, the disappearance of germinative centers is observed. Irregular forms (32.4%) of LU are detected, which are not detected in the spleen of healthy rats. The width of the mantle, marginal, and periarterial zones decreases, as well as the total number of lymphocytes in the LU without a breeding center and PALM by 1.35 and 1.34 times, respectively. These data indicate that radioactive radiation has a negative effect on the lymphoid formations of the spleen, causing the development and formation of immunodeficiency.

Keywords: white rats, immune system, spleen, lymphocytes, lymphoid follicles, chronic radiation sickness.

Introduction. One of the most dynamic systems of the body is the immune system of humans and animals, which quickly reacts to the impact of external adverse factors. Immune organs provide protection from various pathogenic influences [2,3,8].

Among the peripheral organs of the immune system, the largest and most complex organ is the spleen, which performs filtration, cleansing, immune, hematopoietic and depositing functions [6, 9,10].

According to researchers from various countries, the immune system disease associated with environmental pollution is currently increasing in the world. [7,11].

To date, radiation remains one of the most adverse factors that affect the human body. Radiation has the most destructive effect on the human body and causes profound changes in all organs and systems. [1,4,5].

Today, the study of the health status of a person exposed to radiation from various sources of ionizing radiation is an urgent and important problem in science and health. Taking into account the above we set the task of studying the morphological parameters of the spleen of white rats in normal and chronic radiation sickness.

Purpose: to study morphofunctional features of spleen lymphoid structures in 3-month-old white rats in normal and chronic radiation sickness.

Material and methods of research. The study was conducted in 22 mongrel white male rats with a weight of 90 to 130 g, which were kept in standard vivarium conditions. The rats were divided into 2 groups: control group (n=12), 1-experimental group (n=10). Irradiation of rats was performed using the device "AGAT P1 "(Baltiets plant" Narva, Estonia, 1991 year of manufacture, operation since 1994, recharge 2007) with a capacity of 25,006 SGR/ min for 20 days at a dose of 0.2 G. The total radiation dose for rats up to 90 days of age was 4.0 Gy. All experimental studies on animals were conducted in accordance with the "Rules for conducting work using experimental animals".

The animals were weighed and removed from the experiment at 90 days of age by instant decapitation under ether anesthesia.

The spleen was removed from the abdominal cavity. To conduct morphological and morphometric studies of the study, spleen fragments were fixed in a 10% formalin solution, passed through a battery of alcohols and poured into paraffin blocks according to generally accepted methods. Paraffin sections

with a thickness of 5-8 microns were stained with hematoxylin-eosin. The sections were examined morphometrically using an eyepiece-micrometer DN-107T/ Model NLCD-307B (Novel, China) measured the diameter of the periarterial lymphatic couplings, lymph nodes and their germinal centers, the width of the mantle, marginal and periarterial zones, the relative area of the white pulp and connective tissue elements of the spleen to the total area of the cut. Measurements were made in five fields of view of each histological section. The fields of view were chosen randomly.

In order to study the cytoarchitectonics of the spleen's lymphoid structures, cells were counted using a NOVEL Model NLCD-307 microscope, at 10x90 magnification, under oil immersion. The cells were counted using a morphometric grid embedded in the eyepiece (10x) of a microscope.

We calculated the total number of lymphocytes, the number of large, medium and small lymphocytes per unit area of the cut in the PALM, in lymphoid nodules without a breeding center.

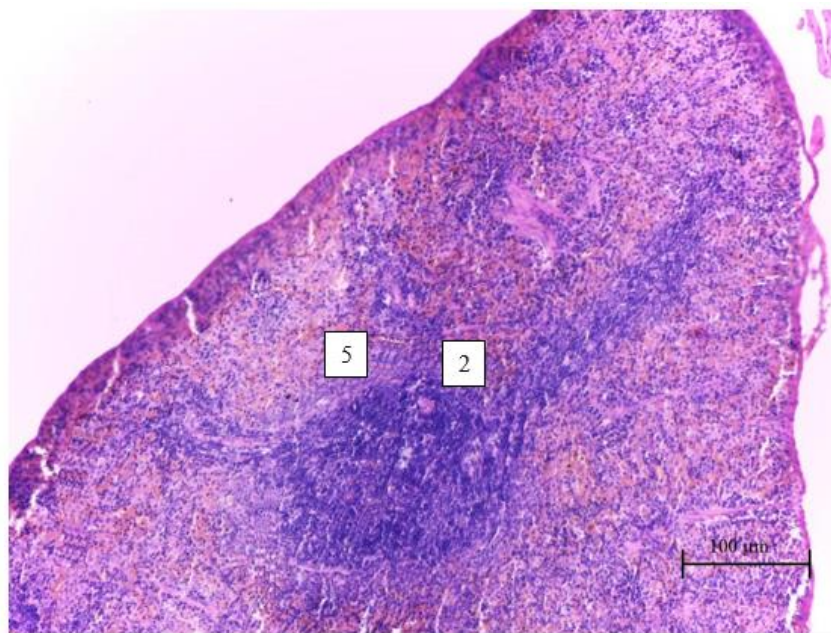
Using directly from the General data matrix "Excel 7.0" on a Pentium-IV personal computer, mathematical processing was performed, and the standard deviation and representativeness errors were determined.

The results of the study and their discussion

When examining the spleen of 3-month-old intact rats, it was found that the relative area of the white pulp ranges from 19.8% to 26.2%, on average-22.2±0.59%. The relative area of connective tissue elements varied from 5.0% to 6.1%, on average-5.52±0.1% (to the total area of the spleen section)

The diameter of the PALM ranges from 122.6 microns to 139.6 microns, with an average of 132.14±1.56 microns. The diameter of the lymph nodes ranges from 341.8 microns to 486.05 microns, with an average of 466.05±13.27 microns. The percentage of primary and secondary LU is 32% and 68%, respectively. The diameter of the germinative centers ranges from 94.6 microns to 167.8 microns, with an average of 147.8±6.73 microns. They are large AND often merge. The LU of the white spleen pulp is generally round, oval, and elongated.

In micro-preparations, you can visually distinguish all the zones of LU. The width of the mantle zone ranges from 39.7 microns to 49.45 microns, with an average of 45.32±0.89 microns. The width of the marginal zone ranges from 70.3 microns to 84.7 microns, with an average of 77.14±1.32 microns. The width of the periarterial zone ranges from 81.9 microns to 89.4 microns, with an average of 85.04±0.69 microns. (pic.1).



1 pic Spleen of a 3-month-old control rat. Painting with hematoxylin – eosin. Oc. 10 x Ob. 20. 1 - lymph node, 2 -periarterial zone, 3-germinal center, 4-mantle zone, 5- marginal zone.

It was found that the total number of lymphocytes in the LU without breeding centers is 42-53, with an average of 47.3 ± 1.01 cells. Lymphoid nodules without centers of reproduction contain (per unit area) small lymphocytes-30-38, on average - 34.0 ± 0.74 cells, medium lymphocytes-10-12, on average - 11.0 ± 0.18 cells, large lymphocytes-2-3, on average- 2.3 ± 0.1 cells.

The total number of lymphocytes in the periarterial lymphoid couplings of the white spleen pulp is 41-53, with an average of 47.2 ± 1.1 cells. Periarterial lymphoid couplings contain (per unit area) small lymphocytes-29-37, on average- 33.0 ± 0.74 cells, medium lymphocytes-9-11, on average - 10.25 ± 0.18 cells and large lymphocytes-3-4, on average- 3.5 ± 0.1 cells.

When studying the spleen of 3 month old rats with chronic radiation diseases the following data were obtained:

The total number of lymphocytes in the periarterial lymphoid couplings of the white spleen pulp is 31-40, on average - 35.2 ± 0.97 cells. The PALM does not contain large lymphocytes. Periarterial lymphoid couplings contain (per unit area) small lymphocytes-24-31, on average- 26.8 ± 0.76 cells, average lymphocytes-7-9, on average - 8.4 ± 0.22 cells.

Thus, the relative area of the white spleen pulp in white rats of the intact group is on average $22.2 \pm 0.59\%$, and in rats with chronic radiation sickness, this indicator decreases by 1.52 times and is equal to $14.6 \pm 0.39\%$. The relative area of connective tissue elements in control group rats is on average - $5.52 \pm 0.1\%$, and in rats with chronic radiation sickness there is an increase in this indicator by 1.04 times and is equal to- $5.73 \pm 0.84\%$ (to the total area of the spleen section).

The diameter of the PALM and lymph nodes of the spleen of irradiated rats in comparison with healthy rats is reduced by 1.33 and 2.38 times, respectively, and is on average 99.35 ± 0.98 and 195.81 ± 8.62 microns, respectively. The lymphoid nodules of the spleen of the control group of rats were mostly rounded-oval and elongated, and in rats with chronic irradiation, irregular shapes were determined (32.4%). The diameter of the spleen HZ in rats of the intact group is on average 147.8 ± 6.73 microns, and in rats with chronic radiation sickness, no breeding centers are detected in histopreparations. The width of the mantle, marginal and periarterial zone in healthy rats is $45.32 \pm 0.89 \mu\text{m}$, $77.14 \pm 1.32 \mu\text{m}$ and $85.04 \pm 0.69 \mu\text{m}$, respectively, and in irradiated rats $36.54 \pm 0.87 \mu\text{m}$, 60.26 ± 0.96 and $59.88 \pm 0.88 \mu\text{m}$, respectively.

The total number of lymphocytes in the LU without reproduction centers and periarterial lymphoid couplings of the spleen in control group rats is on average 47.3 ± 1.01 and 47.2 ± 1.1 cells, respectively, and in rats with chronic irradiation 35.1 ± 0.86 and 35.2 ± 0.97 , respectively.

Conclusions.

1. In the lymphoid structures of the spleen of white rats with chronic radiation diseases observed quantitative changes, which are expressed by the relative reduction in area PD, diameter of the PALM, LU.
2. In the lymph nodes of the spleen of irradiated rats, the disappearance of germinative centers is observed. Irregular forms (32.4%) of LU are detected, which are not detected in the spleen of healthy rats. The width of the mantle, marginal, and periarterial zones decreases, as well as the total number of lymphocytes in the LU without a breeding center and PALM by 1.35 and 1.34 times, respectively.
3. These data indicate that radioactive radiation has a negative effect on the lymphoid formations of the spleen, causing the development and formation of immunodeficiency

Literature

1. Baimuradov R. R., Teshayev sh. Zh. Influence of different types of radiation on the male reproductive system // Problems of biology and medicine 2019, №4.2 2 (115). C. 208-210
2. Buklis Yu. V. Study of immune structures of the spleen in the conditions of chronic radiation exposure to the body // Morphology.-2010. - Volume 137. - No. 4. - P. 42.

3. Kiryanov N. A. et al. Morphological characteristics of the immune and endocrine systems in endotoxycosis // *Medical Bulletin of Bashkortostan*. 2013. Vol. 8, No. 6. Pp. 156-158.
4. Teshayev sh. Zh., Baimuradov R. R. Morphological parameters of testes of 90-day-old rats in normal and under the influence of a biostimulator on the background of radiation exposure // *Operative surgery and clinical anatomy* 2020,4 (2), P.22-26.
5. Khasanova DA., Teshayev sh. Zh. Macroanatomy of lymphoid structures of the mesenteric part of the small intestine of rats in normal and on the background of chronic radiation sickness / / *Morphology* 2019, 156 (4), P. 51-55.
6. Chulkova S. V., Stilidi I. S., Glukhov E. V., Grevtsova L. Yu., Ned S. N., Tupitsyn N. N. the Spleen is a peripheral organ of the immune system. The influence of splenectomy on the immune status / / *Bulletin of the N. N. Blokhin Russian Academy of medical Sciences*, vol. 25, no. 1-2, 2014.
7. Karmaus W., Brooks K., Nebe T., Witten J., Obi-Osius N., Kruse H. Immune function biomarkers in children exposed to lead and organochlorine compounds: a cross-sectional study. // *Environ. Health.* – 2005. – Vol.14. – №1. – P.5.
8. Kour K., Bani S. Augmentation of immune response by chicoric acid through the modulation of CD28|CNLA-4 and Th1 pathway in chronically stressed mice // *Neuropharmacology*. –2010.- V.60, №6. – P. 852-860.
9. Mebius R.E., Kraal G. Structure and function of the spleen // *Nature Reviews Immunology*. 2005. Vol. 5. P. 606–616
10. Turdiyev M. R., Teshayev Sh. J. Morphometric Assessment of Functional Immunomorphology of White Rat Spleen in the Age Aspect *American Journal of Medicine and Medical Sciences* 2019, 9(12): 523-526 DOI: 10.5923/j.ajmms.20190912.16.
11. Udoji F., Martin T., Etherton R., Whalen M.M. Immunosuppressive effects of triclosan, nonylphenol, and DDT on human natural killer cells in vitro. // *J. Immunotoxicol.*–2010. – Vol.7. - №3. – P.205-212